

Periprosthetic Total Ankle Replacement Fractures

Zachary P. Hill, DPM¹, Joseph R. Brown, DPM¹, Daniel DeGenova, DO², Benjamin Taylor, MD, F.A.A.O.S.³

1. Resident, OhioHealth Grant Medical Center 2. Resident, OhioHealth Doctors Hospital 3. Fellowship Director, Orthopedic Trauma Reconstructive Services, OhioHealth Grant Medical Center

Statement of Purpose

Traumatic periprosthetic fractures around total ankle replacements (TAR) are rare, with less than 13 cases reported. TAR usage continues to rise, thus periprosthetic fractures will likely increase. Literature discussing classification, treatment, and outcomes of this pathology is sparse. We present a case report and proposed classification system of postoperative periprosthetic ankle fractures based on location, implant stability, and surrounding bone quality to assist in guiding treatment and improving outcomes. Similar classifications have been validated for periprosthetic knee and hip fractures.

Case Study

A retrospective review of a prospectively collected database exhibited 2 patients who suffered a postoperative traumatic periprosthetic fracture of the tibia, and/or fibula, in the setting of TAR, after a ground level fall. Consent and approval were obtained before study initiation. This database included all ankle fractures treated operatively at a level-one trauma center from 2015 to 2023, yielding a total of 419 screened patients.

Both patients underwent operative fixation by a fellowship-trained orthopedic trauma surgeon utilizing plate and screw instrumentation according to the fracture pattern and soft tissue envelope. A minimally invasive approach was utilized for fixation placement. The fixation construct for each patient included a tibial plate with locking and nonlocking screws. One patient required fibular fixation utilizing a single intramedullary screw. The other had fibular and medial malleolar fixation placed prior to TAR, which was retained (Figures 1-4). There were no other uses of fixation adjuncts in this series. Each was followed at appropriate intervals with radiographic and clinical evaluation. Patients were allowed immediate range of motion (ROM) of the ankle; however, weight-bearing status was managed according to surgeon preference but not beginning earlier than 6 weeks post-operatively.

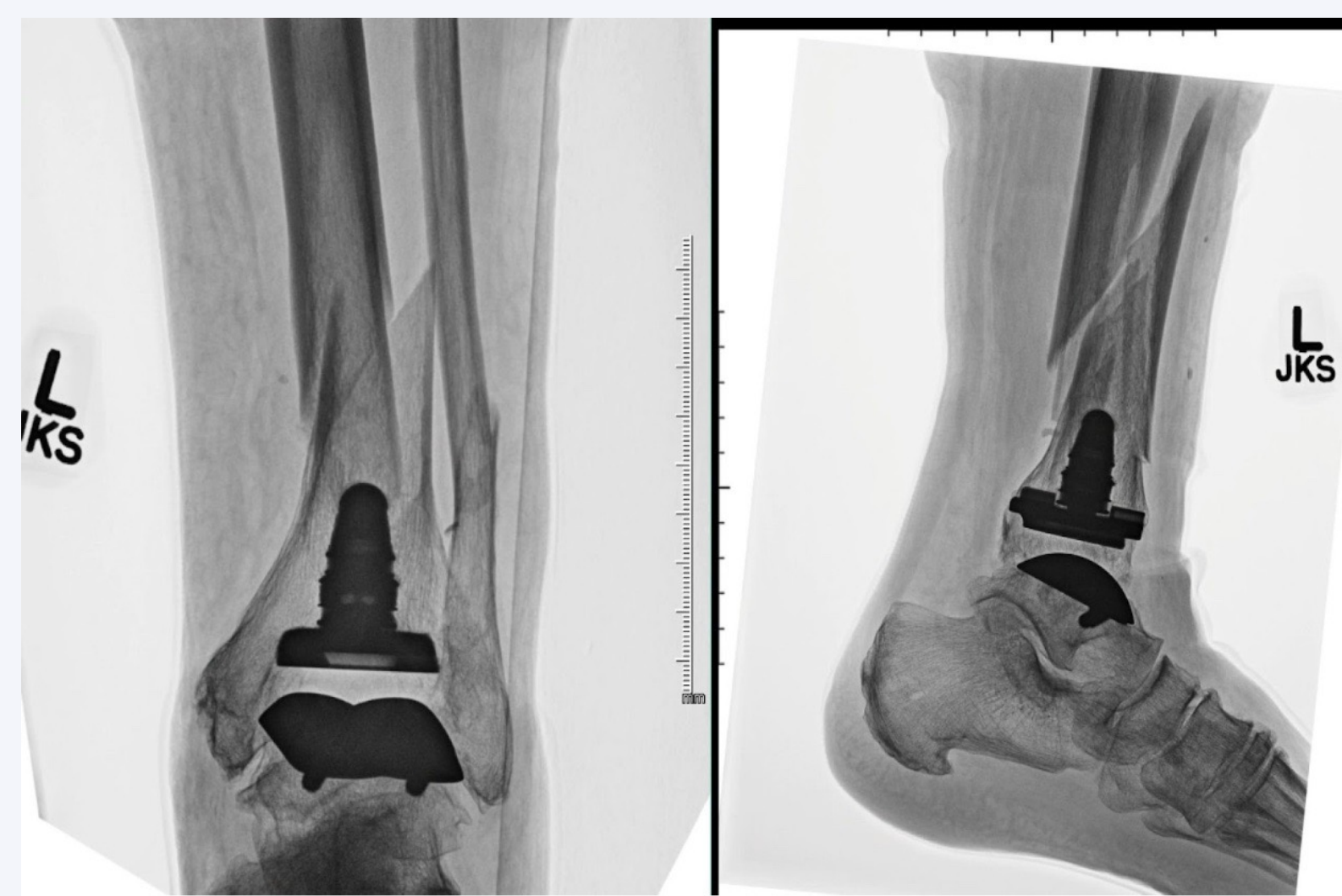


Figure 1: Patient 1 Anteroposterior (left) and lateral (right) radiographs of a 76-year-old female with a previous total ankle arthroplasty who presented after a fall and sustained a traumatic periprosthetic ankle fracture. This represents a Hill-Brown type AF/B1 fracture as shown in Table 1.

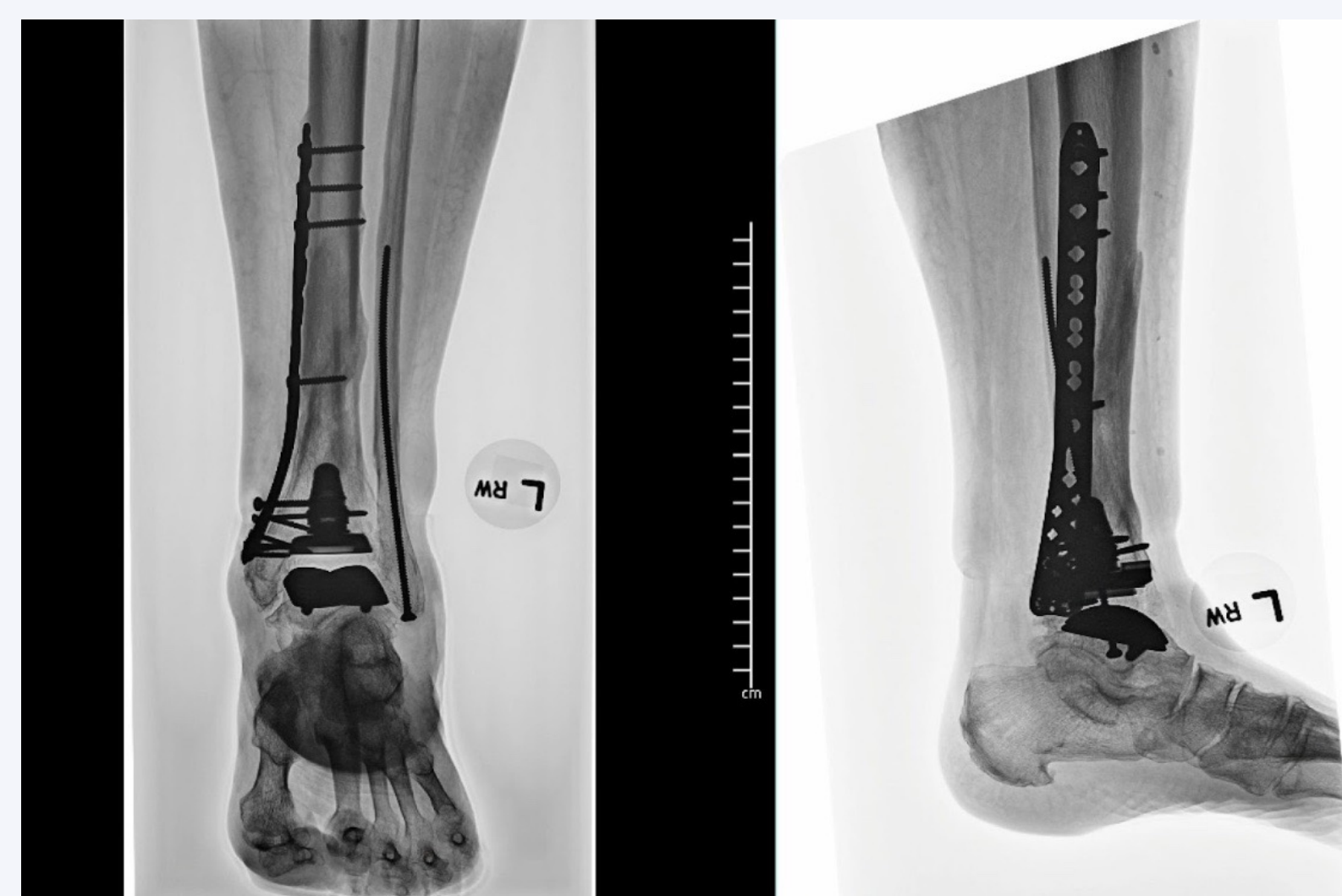

Figure 2: Patient 1 Anteroposterior (left) and lateral (right) radiographs of a 76-year-old female of Figure 1 four months after stabilization with tibial locking screw and plate technology with a hybrid combination of locking and non-locking screws. The fibula was stabilized and fixated with a solid intramedullary screw. Union of the fracture sites is noted with a stable implant.

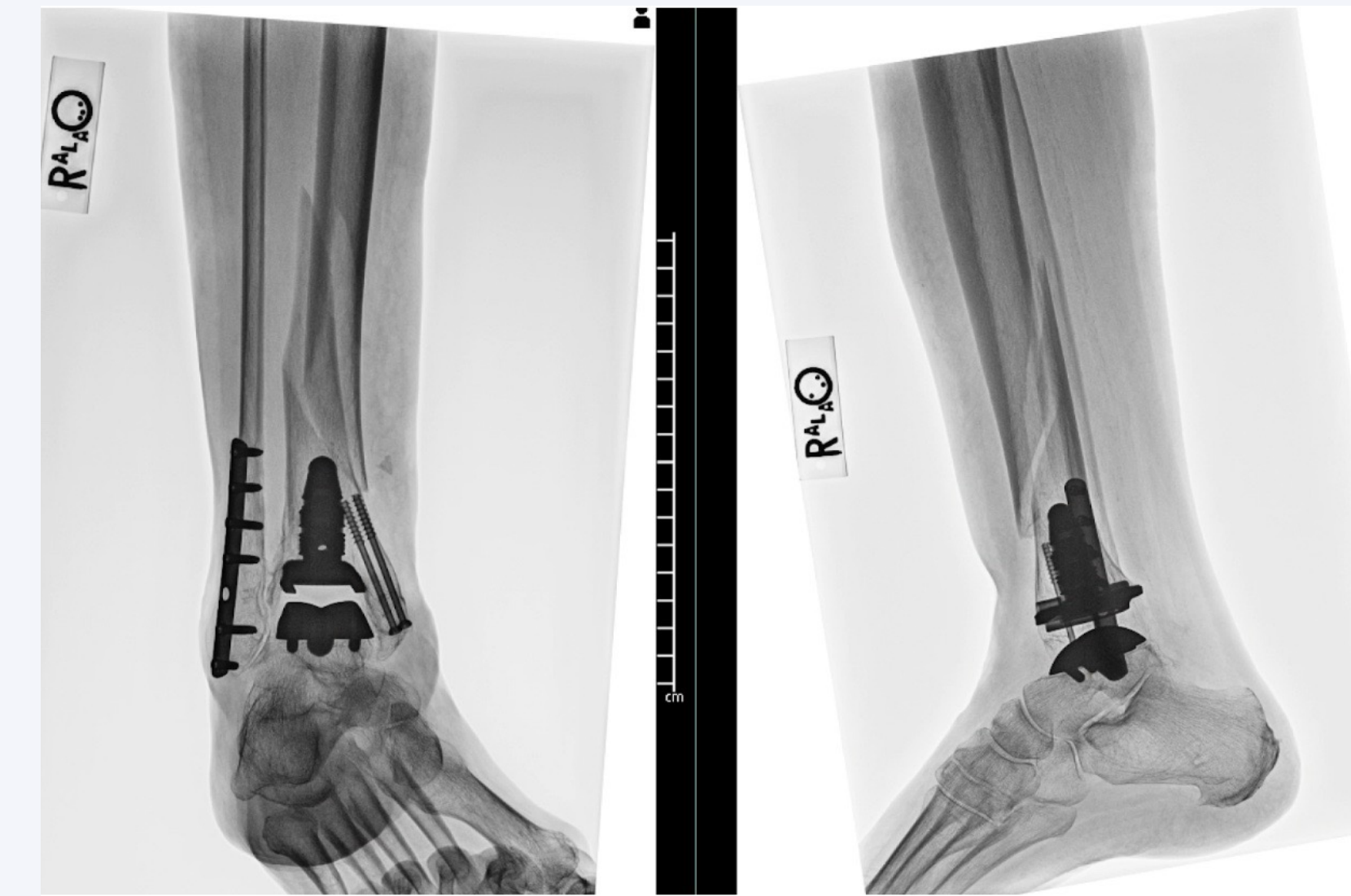


Figure 3: Patient 2 Anteroposterior (left) and lateral (right) radiographs of a 74-year-old female with a previous total ankle arthroplasty who presented following a fall and sustained a traumatic periprosthetic ankle fracture. The lateral and medial malleolar fixation was placed prior to the total ankle implant and fall. This represents a Hill-Brown Type B1 fracture as shown in Table 1.

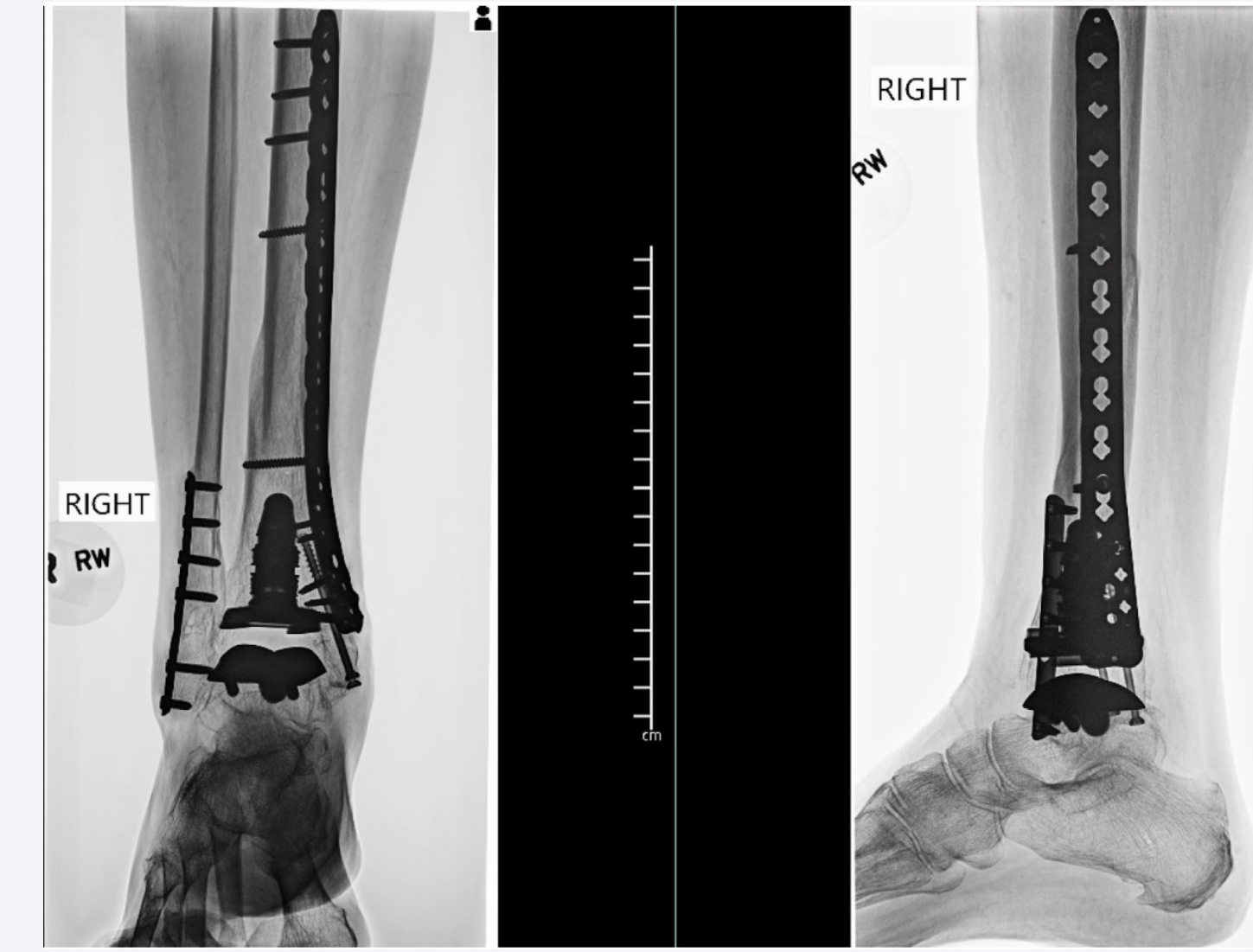


Figure 4: Patient 2 Anteroposterior (left) and lateral (right) radiographs of a 76-year-old female of Figure 3 at six months after stabilization with locking screw and plate technology with a hybrid combination of locking and nonlocking screws. Union of the fracture sites is noted with a stable implant.

Classification Methodology

Hill-Brown Classification of Postoperative Periprosthetic Ankle Fractures			
Type	Subtype	Description	Treatment
A	AT	Talus	Revision TAR or ankle fusion
	AF	Fibula	Consider ORIF if displaced > 2.0cm
B	B1	Fracture at or above the tibial component, with a stable prosthesis	ORIF with locking plate
	B2	Fracture at or above tibial component, with unstable prosthesis but adequate bone stock	Revision TAR with long stem tibial component/ adjunctive fixation or ankle fusion
	B3	Fracture at or above tibial component, with unstable prosthesis/poor bone stock or comminution	Revision TAR with long stem tibial component/adjunctive fixation or ankle fusion + augmentation of bone stock with structural graft
C		Fracture well above tibial prosthesis (tibial shaft)	ORIF with locking plate vs. Antegrade tibial intramedullary nail

Table 1: Proposed Hill-Brown Classification of Postoperative Periprosthetic Ankle Fractures. This proposed classification is based on location, stability of the implant, and the surrounding bone stock as described above.

The proposed Hill-Brown classification of traumatic postoperative periprosthetic ankle fractures includes three separate considerations: fracture location, implant stability, and surrounding bone quality. (Table 1) This classification is based on the previously described and validated Vancouver classification for periprosthetic fractures about total hip replacements.¹

The first consideration is fracture location, noted as Type A, B or C. Type A; is a traumatic periprosthetic fracture located outside of the tibia, further categorized as type AT located at the talus or type AF located at the fibula. Type B; a periprosthetic fracture located at, or slightly above, the tibial implant component. Type C; a periprosthetic fracture located well above the tibial component within the diaphysis to the proximal metaphysis of the tibia.

The second, and most important, consideration is the implant stability. Type B fractures are further categorized as B1, B2, or B3, considering stability and our third parameter, bone stock quality. Implant stability was determined by previously described methods.^{2,3} B1; denotes a fracture at or above the tibial component with a stable prosthesis. B2; indicates a fracture at or above the tibial component with an unstable prosthesis, and poor bone stock or comminution.

Results

Both patients were elderly females with an average age of 75 years. Patient 1 was a 76-year-old female presenting with a Hill-Brown type AF/B1 (Figure 1), while patient 2 was a 74-year-old female presenting with a Hill-Brown type B1 (Figure 2) periprosthetic ankle fracture. One patient had a past medical history of osteoporosis as well as well-controlled diabetes. Neither had a history of inflammatory arthritis. The implant used for each patient included a long-stemmed tibial component.

Mean follow-up was 12 months. The fractures were plated using locking screw and plate technology with a combination of locking and nonlocking screws. A minimally invasive incisional approach was utilized for osteosynthesis. Both patients (100%) achieved osseous union of their fracture site(s) at an average of 5 months. Neither patient required revisional surgery at the time of latest follow-up. No wound-healing complications or superficial/deep infections were encountered postoperatively. The postoperative ankle range of motion (ROM) was full without limitations for both patients. Preoperative ROM could not be assessed secondary to the traumatic nature of the injuries. Both patients were able to return to their previous ambulatory function with no restrictions or ambulatory aids.

Analysis and Discussion

Traumatic postoperative periprosthetic ankle fractures around TARs are rare injuries. The incidence, in the setting of a TAR, at our level 1 trauma center is less than 1% (2/419). Similar incidences have been found in studies of equal size.^{2,4} To the best of the authors' knowledge, less than 13 traumatic cases have been reported, none involving long-stemmed tibial component total ankle implants.^{2,4-9} However, stress fractures about this style of implant have been described.¹⁰ Though rare, these injuries pose reconstructive challenges to the surgeon. There is a paucity of literature describing the characteristics and outcomes of these fractures treated operatively.

Classification, treatment, and outcomes of these complex fractures have rarely been described.^{1,4} The previous classification system for periprosthetic ankle fractures by Manegold² and colleagues recommended operative intervention for all traumatic postoperative periprosthetic fractures (Type 2). These fractures were found to be least prevalent, accounting for less than 1% of the total TARs screened, like the current study. Their proposed classification and treatment, though well-constructed, primarily addressed intraoperative and stress fractures, with little emphasis on postoperative traumatic fractures or the surrounding bone stock. We sought to construct a comprehensive classification for postoperative periprosthetic ankle fractures guided by patient outcomes, current literature, and validated variables/treatment recommendations for periprosthetic fractures surrounding the hip and knee.^{2,11,12,13}

References

- Duncan CP, Maeri BA. Fractures of the femur after hip replacement. *Instr Course Lect*. 1995;44:293-304.
- Manegold S, Haas NP, Tsiolionis S, Springer A, Mirdan S, Schaser KD. Periprosthetic fractures in total ankle replacement: classification system and treatment algorithm. *J Bone Joint Surg Am*. 2013 May 1;95(9):1515-20. doi: 10.2196/JBJS.L.00572. PMID: 23636168.
- Lazarides AL, Vovos TJ, Reddy GB, DeOrio JK, Easley ME, Nunley JA, Adams SB. Algorithm for Management of Periprosthetic Ankle Fractures. *Foot Ankle Int*. 2019 Jun;40(6):615-621. doi: 10.1177/1071100719834542. Epub 2019 Feb 27. PMID: 30813821.
- Tsiolionis S, Schaser KD, Wichlas F, Haas NP, Manegold S. Functional and radiological outcome of periprosthetic fractures of the ankle. *Bone Joint J*. 2015 Jul;97-B(7):950-4. doi: 10.1302/0301-620X.97B7.34871. PMID: 26193951.
- Brock AK, Tan EW, Shafiq B. Post-Traumatic Periprosthetic Tibial and Fibular Fracture After Total Ankle Arthroplasty: A Case Report. *J Foot Ankle Surg*. 2017 Jan Feb;56(1):196-200. doi: 10.1053/j.jfas.2016.01.045. Epub 2016 Mar 2. PMID: 26946999.
- Haendlmayr KT, Fazly FM, Harris NJ. Periprosthetic fracture after total ankle replacement: surgical technique. *Foot Ankle Int*. 2009;30:1233-1234.
- Doets HC, Brand R, Nelissen RG. Total ankle arthroplasty in inflammatory joint disease with use of two mobile-bearing designs. *J Bone Joint Surg Am*. 2006 Jun;88(6):1272-84. doi: 10.2106/JBJS.E.00414. Erratum in: *J Bone Joint Surg Am*. 2007 Jan;89(1):158. PMID: 16757761.
- Henricson A, Knutson K, Lindahl J, Rydholm U. The AES total ankle replacement: A mid-term analysis of 93 cases. *Foot Ankle Surg*. 2010 Jun;16(2):61-4. doi: 10.1016/j.jfas.2009.08.001. Epub 2009 Jul 25. PMID: 20463135.
- Yang JH, Kim HJ, Yoon J-R, Yoon Y-C. Minimally invasive plate osteosynthesis (MPO) for periprosthetic fracture after total ankle arthroplasty: a case report. *Foot Ankle Int*. 2011;32:200-204.
- Adams SB Jr, Demetracopoulos CA, Queen RM, Easley ME, DeOrio JK, Nunley JA. Early to mid-term results of fixed-bearing total ankle arthroplasty with a modular intramedullary tibial component. *J Bone Joint Surg Am*. 2014 Dec;3(96(23)):1983-94. doi: 10.2106/JBJS.M.01306. PMID: 25471913.
- Triplet JJ, Taylor BC, Brewster J. Outcomes and Review of Periprosthetic Tibial Fractures. *Orthopedics*. 2020 May 1;43(5):152-166. doi: 10.3928/01477447-20200213-02. Epub 2020 Feb 20. PMID: 32077969.
- Masri BA, Meek RM, Dundac CP. Periprosthetic fractures evaluation and treatment. *Clin Orthop Relat Res*. 2004;420:80-95. doi: 10.1097/00003086-200403000-00012.
- Rayan F, Dodd M, Haddad FS. European validation of the Vancouver classification of periprosthetic proximal femoral fractures. *J Bone Joint Surg Br*. 2008;90:1576-1579. doi: 10.1302/0301-620X.90B12.20681.